



Summary Feedback

ST1: Two Year Teaching Programme

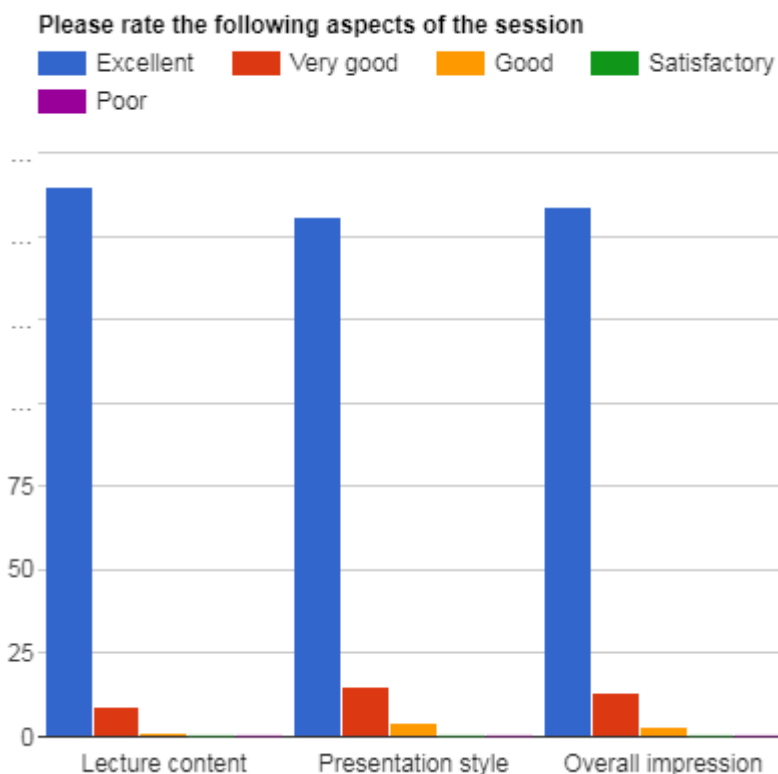
Session 12.1: Essentials of Breast Imaging for FRCR Exam (8th December 2022)

Delivered By:

(Asiya Khan, Muhammad Ahsan Saleem,
Naveed Altaf & Noreen Rasheed)

Summary Points:

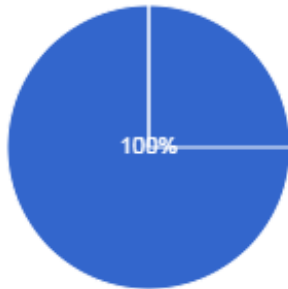
- ST1-ST4 teaching session 12.1: 3 hours teaching time
- Total Attendees: 452 from 35 Countries (Algeria, Bahamas, Bahrain, Botswana, Canada, China, Czech Republic, Egypt, Hong Kong, India, Indonesia, Iraq, Jordan, Kenya, Kuwait, Malaysia, Myanmar, Nepal, Nigeria, Oman, Pakistan, Poland, Qatar, Saudi Arabia, South Africa, Sri Lanka, Sudan, Swaziland, Tanzania, Turkey, UAE, UK, Yemen, Zambia, Zimbabwe).
- Total feedback received from 175 participants



Session 12.1: Essentials of Breast Imaging for FRCR Exam

Did you find it useful
175 responses

● Yes
● No



Testimonials

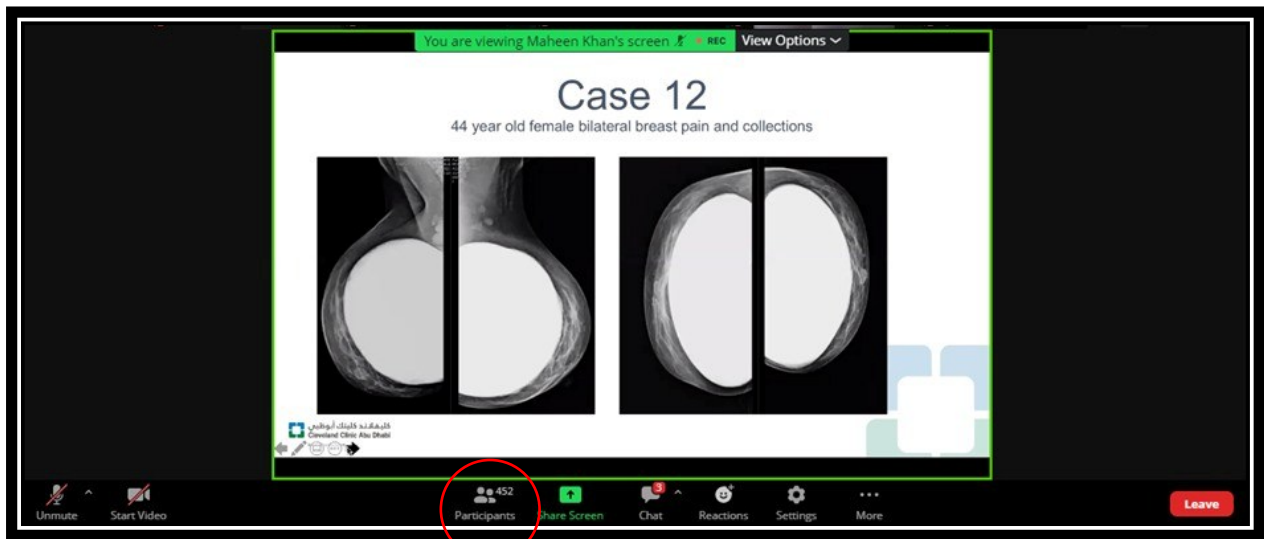
- I really feel privileged to have this class. Thank you very much for these classes.. please do these type of classes more (India).
- It's outstanding way of learning while sitting far away (Saudi Arabia).
- It covered most of the aspects of breast imaging with different cases, concise, informative (Sudan).
- "Crisp, quick and complete grading of breast masses like a spotter. Hopefully may score 8 after this presentation. Excellent orientation about UK style of reporting breast mammogram, ultrasound and MRI" (Pakistan).
- Big Thank You for this lecture. Everything including exam strategy was well explained (Nigeria).
- "Excellent sessions. I would like to thank DKT for this initiative and the milestone they have achieved thus far... Very grateful" (Zambia).
- Great effort by the DKT team as usual (Saudi Arabia).
- Good informative session (Pakistan).
- You are doing an excellent job keep it up , will be good if recordings are available for revise again (Pakistan).
- Simply informative (Pakistan).
- Brilliant (UK).
- Highly recommended to others in future (Saudi Arabia).
- Excellent session as usual (Algeria).
- Best (Pakistan).
- Good lecture.
- Great thanks (Yemen).
- Thank you sir Sami and team (Pakistan).
- Amazing (Saudi Arabia).
- Very good, good tips on how to describe lesions, good multimodality images (UK).
- Very impressive (Qatar).
- Excellent as always (India).
- Awesome but students need time and understanding (Saudi Arabia).
- Nice session (Oman).

Session 12.1: Essentials of Breast Imaging for FRCR Exam

- Excellent teaching sessions (Pakistan).
- Useful. Thank you (UAE).
- Excellent. Need more sessions from her (Pakistan).
- Good. Today was my first class. I enjoyed it (India).
- Excellent recap of breast radiology (Kenya).
- Thank you and well done (UK).
- Excellent thank you so much (Egypt).
- Brilliant as always (UAE).
- Extraordinary (Pakistan).
- Superb session (Pakistan).
- Excellent description (Pakistan).
- Very helpful (UK).
- Great session (South Africa).
- Superb sessions (India).
- Very informative and worthwhile (India).
- Very helpful (Pakistan).
- Very useful and informative (Saudi Arabia).
- Excellent job (Pakistan).
- Nice session as ever (Pakistan).
- Very useful, lots of cases to practice and learn from (Lebanon).
- Everything awesome (Pakistan).
- All awesome work (Qatar).
- Very nice and informative. Need more sessions (Pakistan).
- Just Keep going please (Pakistan).
- Very good (Pakistan).
- Very nice cases.
- Very informative session (Pakistan).
- Excellent cases (UK).
- Excellent variety of cases! (Myanmar).
- Great (Pakistan).
- "Great explanation of cases, Amazing cases" (Pakistan).
- Good range of cases (UK).
- The cases were very good (Kenya).
- Very good cases of mammogram and breast imaging (Pakistan).
- Every case was very well elaborated (Pakistan).
- Valuable lecture.
- Breast cancer is the commonest cancer among women. It's important to know the depth of each and every detail about the disease (Saudi Arabia).
- Very interesting cases to learn (UK).
- Amazing teaching for the breast module (Saudi Arabia).
- Loved the class. Very instructive.
- Many interesting cases and very informative (Egypt).
- The last viva session was the best (UK).
- Nice cases and nice discussion (Egypt).
- Very, very informative session (Oman).
- Excellent Teaching Sessions By Great Dr Khan and his Brilliant team! May Allah bless you in both the worlds. Aamin (Pakistan).

Session 12.1: Essentials of Breast Imaging for FRCR Exam

- Exam oriented preparation and case presentation (Saudi Arabia).
- Improve my knowledge (Indonesia).



Starting 1800 BST



ST1 : Two year Teaching programme

ST 1 - ST 4 Teaching Session 12.1 : Essentials of Breast Imaging for FRCR Exam



Dr Asiya Khan
Consultant Breast Radiologist
Cleveland Clinic, Abu Dhabi



Dr. Muhammad Ahsan Saleem
Consultant Breast Radiologist
University hospital of North Tees
and Hartlepool



Dr. Naveed Altaf
Consultant Breast Radiologist
University hospital of North Tees
and Hartlepool



Dr Noreen Rasheed
Consultant Radiologist with a
Specialist interest in Breast Imagi
Basildon and Thurrock Universit
Hospital

Session 12.1: Essentials of Breast Imaging for FRCR Exam

Recording... You are viewing Maheen Khan's screen View Options

Case 16

Talking: Maheen Khan



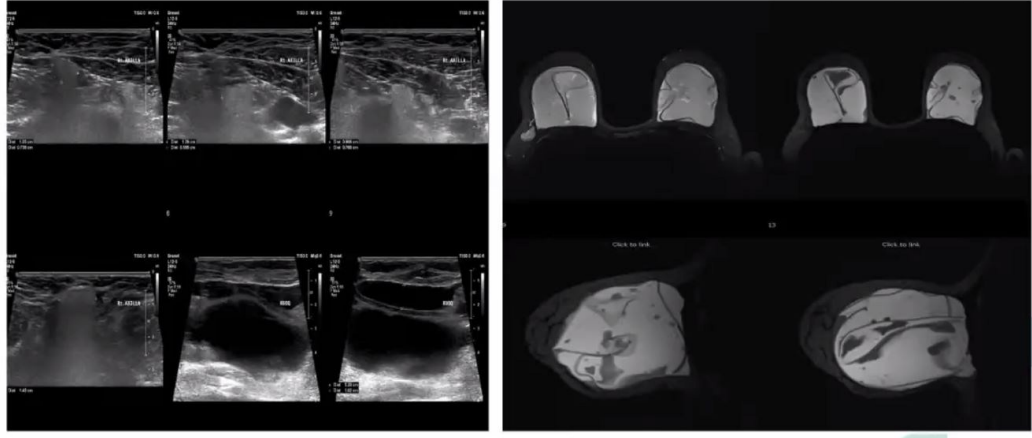
كليفاند كلينك أبوظبي
Cleveland Clinic Abu Dhabi

Unmute Start Video Security Participants 449 Polls Chat 34 Share Screen Pause/Stop Recording Reactions Apps Whiteboards End

Detailed description: This slide displays four mammography images of a breast. From left to right: a craniocaudal (CC) view, a mediolateral oblique (MLO) view, a craniocaudal (CC) view with a palpable mass indicated by a white dot, and another MLO view with a palpable mass indicated by a white dot. The images show varying degrees of breast density and the presence of a focal area of concern.

Recording... You are viewing Maheen Khan's screen View Options

Talking: candidate 1



Unmute Start Video Security Participants 449 Polls Chat 25 Share Screen Pause/Stop Recording Reactions Apps Whiteboards End


Detailed description: This slide shows a collection of breast imaging studies. On the left, there are six ultrasound images arranged in a 2x3 grid, showing various cross-sections of breast tissue with some areas of increased echogenicity. On the right, there are six breast MRI images arranged in a 2x3 grid, showing axial and coronal views of the breast with contrast enhancement, highlighting areas of abnormal enhancement.

Session 12.1: Essentials of Breast Imaging for FRCR Exam

Recording... You are viewing Maheen Khan's screen View Options

Case B 1

Talking: Maheen Khan



كليه كليفلاند كوينك أبوظبي
Cleveland Clinic Abu Dhabi

Unmute Start Video Security Participants 438 Polls Chat Share Screen Pause/Stop Recording Reactions Apps Whiteboards End

=====XX=====XX=====